IN THE HIGH COURT OF ANDHRA PRADESH AT AMARAVATI

WEDNESDAY, THE TWENTY SECOND DAY OF APRIL

TWO THOUSAND AND TWENTY SIX

: PRESENT:

THE HONOURABLE SRI JUSTICE K SURESH REDDY

AND

THE HONOURABLE SRI JUSTICE A. HARI HARANADHA SARMA

IA No. 2 OF 2026

IN

CRLA NO: 691 OF 2024

Between:

Yerramuddaiah Gari Vijay Kumar@ Boya Sake Vijay Kumar, Aged about 29 years S/o Late Mallobulesu, D.No 2-90, Kandukuru Village, Ananthapuramu Rural Mandal

...Petitioner

(Petitioner in CRLA No. 691 OF 2024

on the file of High Court)

AND

State of Andhra Pradesh, represented through Public Prosecutor at High Court, Amaravathi.

...Respondent

(Respondents in-do-)

Petition under Section 528 of BNSS is filed praying that in the circumstances stated in the grounds filed in support of the petition, the High Court may be pleased to extension interim order dated 19.02.2026 I.A.No.1/2026 in CRLA No.691/2024 for another 4 months,Pending disposal of CRLA No. 691 of 2024, on the file of the High Court.

The court while directing issue of notice to the Respondents herein to show cause as to why this application should not be complied with, made the following order.(The receipt of this order will be deemed to be the receipt of notice in the case). The Court made the following

The Appeal coming on for hearing and upon perusal of the Petition and grounds filed in support thereof and the earlier Orders of the High Court dated 11.12.2025 vide IA No.3 of 2025 and 17.12.2025 vide IA No.4 of 2025, and 31.12.2025 vide IA Nos. 5 and 6 of 2025, and 19.02.2026 vide IA No.1 of 2026, and upon hearing the arguments of Sri N. Ranga Reddy, Advocate for the Petitioner and of Public Prosecutor for Respondent, the Court made the following

ORDER

This Court, by order dt. 11.12.2025, granted bail to the petitioner, which was modified by order dt. 31.12.2025. The said bail was granted from 31.12.2025 to 23.02.2026, which was further extended from 23.02.2026 to 22.04.2026. The petitioner was directed to surrender by 05.00 P.M. on 22.04.2026 without fail.

Now, the petitioner filed present I.A. seeking to extend the bail for another period of four months.

Sri N.Ranga Reddy, learned counsel for the petitioner, contends that after granting bail, the petitioner took treatment in National Institute of Mental Health and Neuro Sciences, Bangalore [NIMHANS]. He further contends that the health condition of the petitioner has not become normal. Now, he is taking treatment in NIMHANS as an Outpatient by staying at Ananthapuramu town. He also annexed the MRI Report–BRAIN dt. 04.03.2026 issued by the Government General Hospital, Ananthapuramu as well as the Case sheet dt.09.03.2026 issued by the

NIMHANS. As such, he requests this Court to extend the bail for another period of four months.

Learned counsel for the unofficial respondent opposed the bail application.

In view of the above facts and circumstances, this Court is inclined to extend the bail, granted to the petitioner, till 29.06.2026.

Post this I.A. on 22.06.2026.

In the meanwhile, Registry is requested to forward the Medical certificates, annexed to the present I.A., to the Superintendent, Central Prison, Kadapa, who in turn, has to get the information / clarification from the Medical Officer attached to the Central Prison, Kadapa as to whether the treatment can be available to the petitioner at the Central Prison, Kadapa.

Further, the Medical Officer, Central Prison, Kadapa is also permitted to take the assistance of the Doctors at Rajiv Gandhi Institute of Medical Sciences (RIMS), Kadapa to ascertain the availability of treatment for the petitioner at RIMS.

The Superintendent, Central Prison, Kadapa is directed to furnish a report to this Court on or before 22.06.2026, without fail.

Sd/-U.SRIDEVI
DEPUTY REGISTRAR

//TRUE COPY//

SECTION OFFICER

P

To,

1. The Registrar (Judicial), High Court of AP
2. The Superintendent, Central Prison, Kadapa (Enclosure – Medical Certificates of the Petitioner)
3. One CC to Sri N Ranga Reddy, Advocate [OPUC]
4. One CC to Sri Gundala Siva Prasada Reddy, Advocate [OPUC]
5. Two CCs to Public Prosecutor, High Court of Andhra Pradesh [OUT]
6. One spare copy

HIGH COURT

KSR, J
&
AHHS, J

DATED: 22/04/2026

POST THIS IA. ON 22.06.2026

ORDER

IA No. 2 OF 2026
IN
CRLA NO: 691 OF 2024

INTERIM DIRECTION

HIGH COURT OF ANDHRA PRADESH
SPECIAL CELL
23 APR 2026
DESPATCHED

NIMH/MRD/FORM/V1/2020/0005

ರಾಷ್ಟ್ರೀಯ ಮಾನಸಿಕ ಆರೋಗ್ಯ ಮತ್ತು ನರ ವಿಜ್ಞಾನ ಸಂಸ್ಥೆ, ಬೆಂಗಳೂರು
राष्ट्रीय मानसिक स्वास्थ्य और तंत्रिका विज्ञान संस्थान, बेंगलूरु
National Institute of Mental Health & Neuro Sciences, Bengaluru-560 029
(An Institute of National Importance)

ಹೊರ ರೋಗಿ ವಿಭಾಗ/ **Out Patient Department** / बाह्य रोगी विभाग

Please Fill all Sections, Write in BLOCK LETTERS

ಓ.ಪಿ./ಐ.ಪಿ./No. OP/IP/ओ.पी. नं./ Vijay Kumar ದಿನಾಂಕ/Date/तारीख 16/03/26

ರೋಗಿಯ ಹೆಸರು ಮತ್ತು ವಿಳಾಸ/Name & Place/नाम और स्थान 20260101716 ವಯಸ್ಸು/Age/आयु

Rx/-

1) T. ECOSPIRIN 150mg 0—1—0

2) T. Atorvastatin 40mg 0—0—1

3) T. Amlodipine 5mg 1—0—0

4) T. Homin 1tab 0—1—0

- R/A 1mon c̄ all documents for RPL
- Speech & Audiology

STOP DRUGS IF THERE IS ALLERGY

Unit.....

Follow Up Date.....

Name.....

Signature.....

ಮಾನಸಿಕ ಸಹಾಯಕ್ಕಾಗಿ, ಟೆಲಿ ಮನಸ್ಸಿಗೆ ಕರೆ ಮಾಡಿ (ಶುಲ್ಕರಹಿತ) - 14416
FOR MENTAL HEALTH SUPPORT, CALL Tele MANAS (TOLL-FREE) - 14416
मानसिक स्वास्थ्य सहायता के लिए, टेली मानस पर कॉल करें (निःशुल्क) - 14416

Tele MANAS 14416

9

NIMH/MRD/FORM/V1/2020/0007

REFERRAL FORM

ರಾಷ್ಟ್ರೀಯ ಮಾನಸಿಕ ಆರೋಗ್ಯ ಮತ್ತು ನರ ವಿಜ್ಞಾನ ಸಂಸ್ಥೆ, ಬೆಂಗಳೂರು – 560 029.
राष्ट्रीय मानसिक स्वास्थ्य एवं तंत्रिका विज्ञान संस्थान, बेंगलूर – 560 029.
National Institute of Mental Health & Neuro Sciences, Bangalore - 560 029.
(An Institute of National Importance)

ಹೊರ ರೋಗಿಗಳ ವಿಭಾಗ / Out Patient Department / बहिरोजी विभाग

Please Fill All Sections, Write in BLOCK LETTERS

ಓ.ಪಿ./ಐ.ಪಿ./ No. OP/IP ओ.पी. नं./..... Date/दिनांक 16/03/26

ರೋಗಿಯ ಹೆಸರು / Name & Place / नाम और पता Vijay Kumar

20260101716

ವಯಸ್ಸು / Age / आयु ..... ಲಿಂಗ / Sex / लिंग..... Income / अधाय.....

The Consultant / Senior Resident
Dear Sir/Madam
Kindly give your opinion for this patient Probable Diagnosis_____

DEPARTMENT	PLACE
NEUROLOGY	F1 / F2 (OPD FIRST FLOOR)
NEURO SURGERY	GATE 3 (GROUND FLOOR
PSYCHIATRY	F14 (OPD FIRST FLOOR)
CHILD ADOLESCENT PSYCHIATRY	CAP 200 (OPD GROUND FLOOR)
SPEECH AND AUDIOLOGY	G14 (OPD GROUND FLOOR)
PSYCHIATRIC SOCIAL WORK	F2 (OPD ROOM NO. 21)
IM (AYURVEDA YOGA/PSYCHIATRY)	G-13 (MON, THUR, FRIDAY)
NEURO PSYCHOLOGY	ASHWINI BLOCK
PHYSIOTHERAPY (PT)	PHYSIOTHERAPY CENTRE (OPP SBI)
DEPT OF NEURO REHAB (DNR)	DPNR BUILDING (OPP SBI)
PSYCHIATRIC REHAB SERVICE (PRS)	DPNR BUILDING (OPP SBI)
YOGA CENTER	NEAR AYUSH BLOCK

Unit_____ Name_____

F/up Day_____ Sign_____

F/up Date & Time_____ Room No_____

10

National Institute of Mental Health and Neurosciences (INI), Bangalore - 29
Department of Speech Pathology & Audiology
Case Sheet

Name: Yarra Vijaykumar Age/Gender: 39yr/M Date: 9/3/26

Referral Source: Neurology SPA No.: 117220 Hospital No: 20260107-16

Language: Telugu Consultant: MS RSR Clinician & Affiliation: Telugu (SLST)

Chief Complaints: (As reported by the patient/guardian) C/O word finding difficulty and slowness of speech

History: K/H/O CVA - left fronto temporal lobe on 14/11/2025

* MRI Impression: chronic infarct in left fronto-temporal lobe. Small vessel ischemic changes in left Centrum Semiovale and complete occlusion of left ICA.

→ Language Evaluation.

1. Spontaneous Speech: Is able to respond fluently, Able to answer all the questions presented in sentences, He was able to ~~answer~~ describe activities & items in picture

2. Auditory Verbal Comprehension:
* Yes/No questions: Is able to answer all the questions appropriately
* Auditory word Recognition: Is able to name all the items without any difficulty
* Sequential Commands: Is able to follow 3-4 step commands

3. Repetition: Is able to repeat 5-6 words with few articulation errors in complex sentences.

4. Naming: * object naming: Is able to name all the objects presented
* word fluency: Is able to name 13 animals in 1 minute
* Sentence Completion: able to complete sentences appropriately
* Responsive Speech: Able answers All the questions appropriately.

National Institute of Mental Health and Neurosciences (INI), Bangalore-29
Department of Speech Pathology and Audiology
Case Sheet

Name: Yarra Vijay Kumar Age/Sex: 39/M SPA No.: 117220 Hospital No.: 20260101716

→ OPME

* Face: symmetrical
* Lips: Protrusion (+)
  Retraction (+)
  elevation (+)
  Lateralization (+)
  DDK (+)
  Rate - Adequate
  Range - Adequate
* Tongue: elevation (+)
  depression (+)
  Rate - Adequate
  Range - Adequate
  Strength - Good
  Lateralization (+)
* Jaw: opening (+)
  Closing (+)
  Lateralization (+)
  Rate - Adequate
  Range - Adequate
* Soft palate - B/L symmetrical velar elevation (+)

→ Subsystem Analysis

Respiration: Abdomino thoracic breathing
SBC - 20/breath

Phonation: /a/ - 15, 14, 14 2 sec
/i/ - 14, 13, 14 sec
/u/ - 13, 14, 13 2 sec

National Institute of Mental Health and Neurosciences (INI), Bangalore-29
Department of Speech Pathology and Audiology
Case Sheet

12

Name: Yuva Vijayakumar Age/Sex: 39/M SPA No.: 117220 Hospital No.: 20260101714

Loudness variability – Adequate as perceived
pitch variability – Adequate as perceived
voice quality – Normal as perceived.

* Articulation: ODK : AMR /Pa/ – 4.2 syll/sec
/ta/ – 4.6 syll/sec
/ka/ – 4.4 syll/sec
SMR (pataka) – 5.1 syll/sec.
Ay JNISHD-1 (Can understand without difficulty however feel speech is not normal)

* Resonance perceptually Normal as perceived
* prosody: Stress, Rhythm, Intonation } Impaired

→ Impression – Moderate Dysarthria secondary to CVA.

→ Advice – Dysarthria Management.
– Speech based oromotor exercises
– Contrastive stress drills.

Rasini Singh
01/03/2026

Department of Speech Pathology and Audiology
National Institute of Mental Health and Neurosciences

GOVERNMENT GENERAL HOSPITAL

ANANTHAPURAMU.
Ph: 08554-222727, Mobile No.: 9550989858
గవర్నమెంట్ జనరల్ హాస్పిటల్ అనంతపురము.
అనంతపురము - 515 001

13

Patient Id	3260304073OP	Name	VIJAY KUMAR.M	Accession No	1096484
Study Date	04-Mar-2026	Referral Dr.	DR.ANAND MS.ORTHO	Age/ Gender	39Y / Male

Clinical History : -

MRI REPORT - BRAIN

TECHNIQUE:

T1W Sagittal, Dw- b1000, ADC, GRE

T2W FS Axial, FLAIR Axial & Coronal

OBSERVATION:

Evidence of altered signal intensity noted in left fronto-temporal lobe showing T1 hypointense, T2 hyperintense partially suppressed on FLAIR,facilitated diffusion on DWI-ADC mapping,no blooming on SWI s/o chronic infarct.

Evidence of T2, FLAIR hyperintensity noted in left Centrum semiovale s/o ischemic changes.

The thalami, basal ganglia and internal capsules are normal on both sides.

The ventricles and sulci are normal for the age.

The pituitary gland, infundibulum and hypothalamus are normal for the age.

The posterior fossa shows normal cerebellum.

The medulla, pons and mid brain shows normal signals in all the sequences.

Both CP angles are clear. The basal cisterns are normal.

Normal flow void is seen in the major dural venous sinuses and arteries.

IMPRESSION:

- Chronic infarct in in left fronto-temporal lobe.
- Small vessel ischemic changes in left Centrum semiovale.

Dr.Suresh MD.RD
Consultant Radiologist

ERNMENT GENERAL HOSPITAL

ANANTHAPURAMU.

Ph: 08554-222727, Mobile No.: 9550989858

గవర్నమెంట్ జనరల్ హాస్పిటల్ అనంతపురము.

అనంతపురము - 515 001

14

Patient Id	3260304074OP	Name	VIJAY KUMAR.M	Accession No	1096485
Study Date	04-Mar-2026	Referral Dr.	DR.ANAND M.S.ORTHO	Age/ Gender	39Y / Male

Clinical History : -

MRI REPORT – BRAIN WITH MR ANGIOGRAM

TECHNIQUE:

T1W Sagittal, Dw- b1000, ADC, GRE

T2W FS Axial, MR Angiogram, FLAIR Axial & Coronal

MR ANGIOGRAM:

Evidence of non-visualization of flow signal intensity noted in left ICA from its cervical, petrous, cavernous, clinoid, ophthalmic,communicating segments with normal flow signal intensity noted in ipsilateral ACA, MCA, via collateral circulation.F/S/O complete occlusion of left ICA.

IMPRESSION:

- **Complete occlusion of left ICA.**

Dr.Suresh MD.RD
Consultant Radiologist

GOVERNMENT GENERAL HOSPITAL ANANTAPUR
Aravind Nagar, Anantapur

15

ABHA Address : 91735345728530@abdm/ Abha No : 91-7353-4572-8530
నమోదు సంఖ్య (Registration No (UHID)) : **20240424203**
Last Visit Date : 11/02/2026 11.30 AM / టోకెన్ సంఖ్య (Token No) : 24
గది సంఖ్య (Room No) : **ADMINISTRATION BUILDING,ENT OP,1st,11**

Dr. Sudhir Kumar Midde

పేరు (Name) : **Mr. Yarra Muddayya Gari Vijay Kumar**
వయస్సు/ లింగం (Age/Sex) : **39Y 1M 25D / M**
విభాగము (Department) : ENT
Unit : UNIT 2
రోగి తరహా (Patient Type) : General
Purpose :

నమోదు ధర (Registration Amount) : **Rs. 0**
మొబైల్ సంఖ్య (Mobile No) :
చిరునామా (Address) :C/O 2-90, kandukuru Anantapur Andhra Pradesh 515721,,ANANTAPUR(ANDHRA PRADESH)
నమోదు తేదీ (Date of Registration) : **26/02/2026 11.05 AM**
MLC Patient : NO
Last Complete Collection Date/Amount : 01/01/2026 12.17 PM/Rs. 0

CVA — Stable in gym 4/3/26
6:30PM

Adv
Ely
Dr Cello
Multiple Angio

26/2/26

2D ECHO REPORT

No RWMA
Normal LV Function (EF-60%)
No Pericardial Effusion
No LV Clot, No Vegetation

Debidatta

ID: 20260226212422 28
Name:
Age:
Gender:

27-02-2026 12:13:23 AM

Vent. Rate	74 bpm
PR Interval	128 ms
QRS Duration	90 ms
QT/QTc Interval	370/395 ms
P/QRS/T Axes	17/61/15 deg
QTc Hodges	

Sinus rhythm
--- Interpretation made without knowing patient's gender/age ---
Inferior T wave abnormality is nonspecific

Borderline ECG

Uncomfirmed Diagnosis.

Vijaykumar

16

16

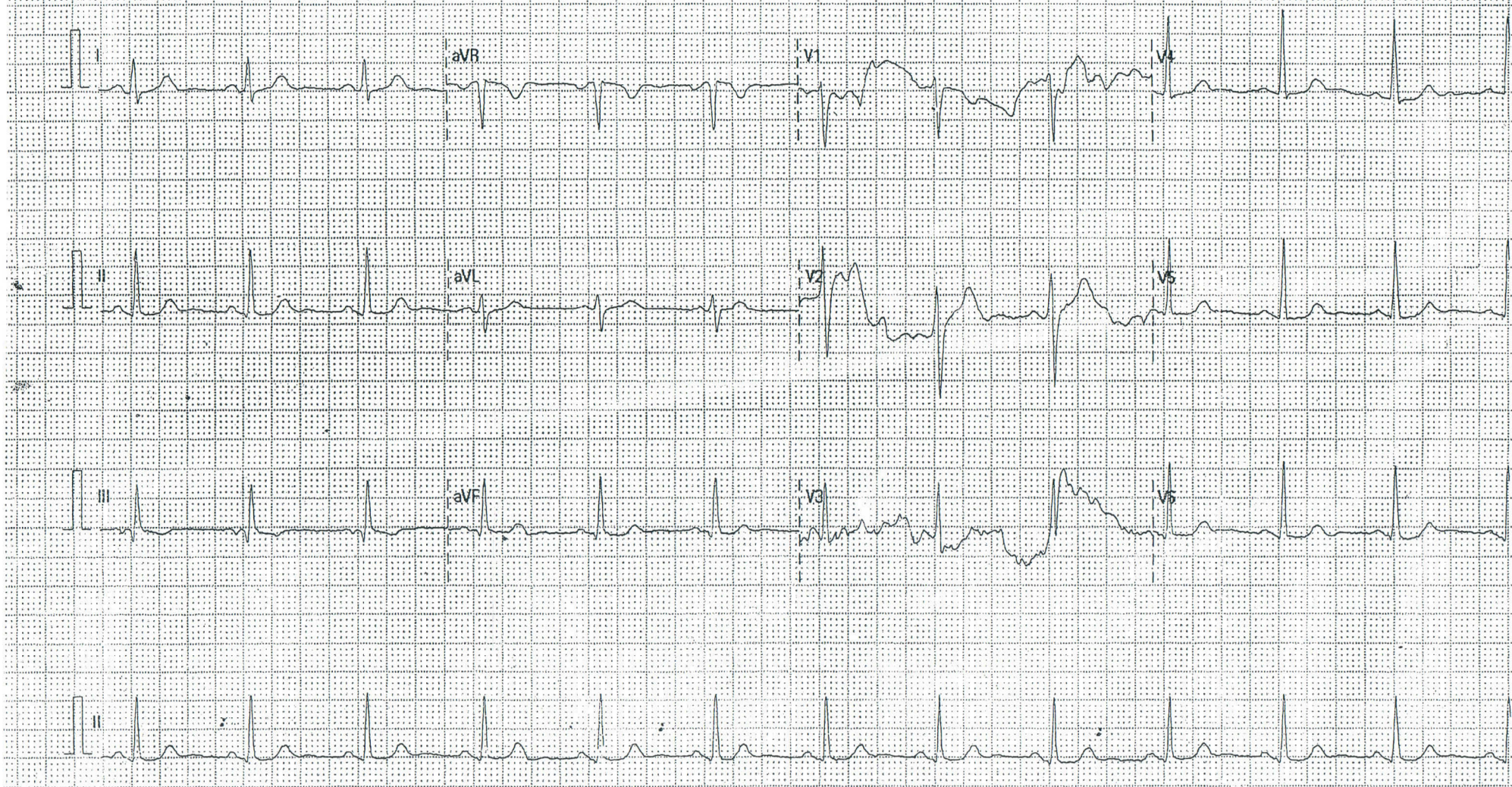

25 mm/s 10 mm/mV 50 Hz BDR 20 Hz Gov General Hospital Anantapur 02.07.00/V28.4.1 SN:EN-83011032

HIGH COURT OF ANDHRA PRADESH
SPECIAL CELL
23 APR 2026
DESPATCHED